

A Postlaminectomy Arteriovenous Fistula Secondary to Traumatic Aneurysm

H. A. Al Zahrani

Saudi Medical Journal 1993; 14(5): 461-463

يعتبر الناسور الشرياني الوريدي بين الأوعية الحرقفية المشتركة والناجم عن ام الدم الحرقفية الاصابية نادر الحدوث الى حد بعيد بعد اجراء عملية استئصال القوس الفقرية الخلفية. وقد واجه المؤلف هذه الحالة بعد سنتين من اجراء عملية صعبة لاستئصال القوس الفقرية الخلفية. وقد اجريت عمليات اصلاح الناسور وقطع ام الدم واعادة انشاء الأوعية بنجاح. المفردات الرئيسية: الناسور الشرياني الرئوي، ام الدم، استئصال القوس الفقرية الخلفية، الاصابة.

Arteriovenous fistula between common iliac vessels and secondary to traumatic iliac aneurysm is extremely rare after laminectomy. Such a case was encountered by the author two years after a difficult laminectomy. Repair of the fistula, excision of the aneurysm, and vascular reconstruction were successfully performed.

Injury to major vessels occurs rarely during surgical removal of a prolapsed lumbar disc. However, when it does occur it is associated with a high incidence of morbidity and mortality if not properly recognized and treated during the operative procedure. The diagnosis of a late complication such as the one described here depends mainly on a high index of suspicion since neither the patient nor the doctor may correlate the symptoms with a previous surgical procedure. The rarity of this serious complication and the growing numbers of disc surgery operations being carried out in our country prompted me to report this interesting case. The English literature is reviewed.

Case History

A 25-year-old unmarried Jordanian female nurse was referred to the Vascular Surgery Service of King Fahad Hospital in Jeddah, Saudi Arabia as a case of suspected leaking right iliac aneurysm detected by an abdominal ultrasound examination in another hospital. Her complaint started 10 days prior to admission to our unit

when she had a continuous diffuse lower abdominal pain, mainly left-sided. There were no other symptoms. She had been operated for a disc prolapse 2 years previously. Postoperatively, she was informed that her operation had been quite difficult.

On examination, she was pale and uncomfortable from the abdominal pain. Her pulse rate was 100/min and her blood pressure was 110/70 mmHg. The abdomen was soft but the lower half was tender on deep palpation. There was a palpable thrill all over the abdomen, maximum over the right iliac fossa and thigh. A harsh machinery murmur was also auscultated in the same area. Examination of the other systems including the vascular examination were almost normal. The right lower limb was swollen with a difference of the circumference measurement of 4 cm at mid-thigh level. Branham's sign was positive. The ankle/brachial index was 0.5 on the right side and 1.0 on the left side.

The full blood count, blood chemistry and chest X-ray were all within normal limits. Electrocardiography showed sinus tachycardia. Urgent abdominal ultrasound showed an aneurysm of the right common iliac artery. In addition, a collection in right iliac fossa and pouch of Douglas were also seen. There was a large left ovarian cyst of about 6 cm diameter. A subsequent computed tomographic (CT) scan of the abdomen confirmed the ultrasound findings. Arteriography demonstrated a right common iliac aneurysm with arteriovenous fistula between right common iliac artery and vein. The latter was hugely dilated and the contrast was seen immediately after injection in the inferior vena cava (Figure 1A, B).

At laparotomy via a mid-line incision there was difficulty in dissecting the common iliac arteries and distal abdominal aorta due to adhesions. A ruptured left ovarian cyst was also found with haemorrhagic fluid in

Department of Surgery, King Abdulaziz University Hospital, PO Box 6615, Jeddah 21452, Saudi Arabia

HASAN ALI AL ZHRANI FRCS (Glas), Assistant Professor and Consultant Vascular Surgeon

Originally submitted: 28.06.92.

Received in final revised form: 20.12.92.

Accepted: 21.12.92.

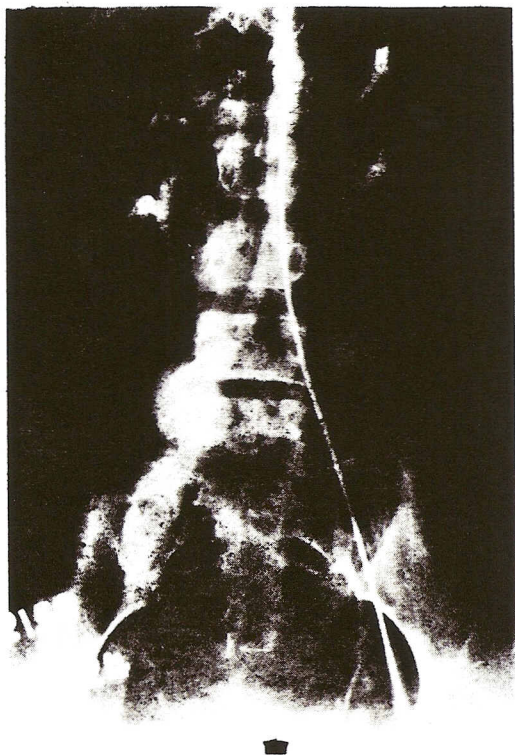


Figure 1A. Aortogram showing arteriovenous fistula between right common iliac artery and vein.

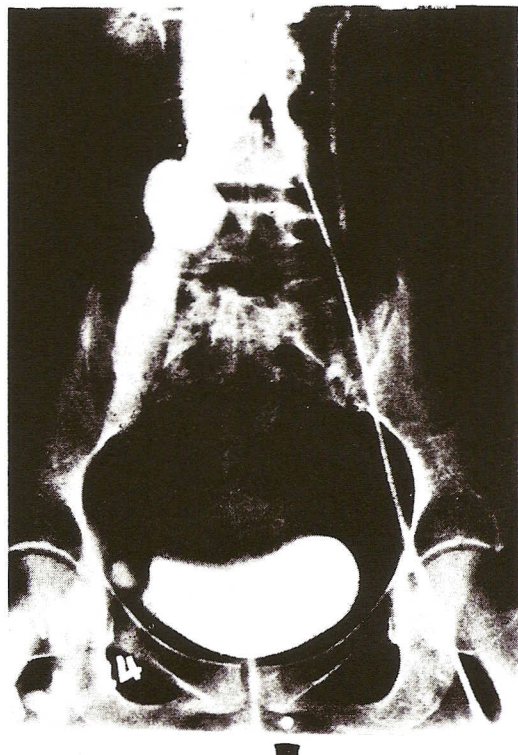


Figure 1B. Close-up view of aortogram shown in Fig. 1A.

the peritoneal cavity and pouch of Douglas. A right common iliac artery aneurysm was seen 5–6 cm distal to the aortic bifurcation, and a harsh thrill was also detected over the iliac vessels. The common iliac artery was clamped and opened at the aneurysm site and a hole of about 1 cm diameter was seen at the posterior aspect of aneurysm with gushing of venous blood. The hole was closed using 6/0 prolene and iliac artery wall as a patch. The right common iliac artery was resected and an 8 mm polytetrafluoroethylene (PTFE) bypass graft was interposed in an end-end fashion (Fig. 2). Finally, the ovarian cyst was dealt with by a gynaecological colleague. The patient's postoperative course was uneventful. The right leg swelling and thrill disappeared. A postoperative nuclear arteriogram demonstrated a patent graft. She was well 1 year after surgery with an ankle/brachial index of 1.0 bilaterally.

Discussion

In 1934, Mixer & Barr described the role of surgery in the treatment of the herniated intervertebral disc.¹ A decade later reports about vascular complications of disc surgery started to appear in the literature.^{2,3} In 1948, Holscher³ wrote after describing his case 'the ease with which this complication can occur, can only be appreciated by the surgeon in whose hands such an

unfortunate incident has happened'. Despite the awareness of its occurrence, reports on this iatrogenic injury continued to appear in the literature.⁴⁻⁶ By 1976, over 70 cases of arteriovenous fistula had been recorded.⁶

The exact incidence of vascular injuries during lumbar disc surgery is unknown⁷ but is definitely underestimated. In our country, it is expected that there will be a steady increase in the numbers of this procedure performed. To my knowledge this is the first case reported in the Saudi literature. The close anatomical relationship between the aorta, the vena cava and the iliac vessels on one side and the vertebral bodies and discs on the other make the possibility of injury to these vital structures very likely if the operating surgeon is focusing only on the orthopaedic aspects. The trauma is usually caused by the pituitary rongeur plunging through the anterior longitudinal spinal ligament. Frequently, the injury will be recognized on the table and the neuro-orthopaedic surgeon will call for urgent help from a vascular surgery colleague. Such an injury will be simple or multiple lacerations which usually leads to serious haemorrhage and shock. Alternatively, as happened in our case minimal haemorrhage may occur and lead

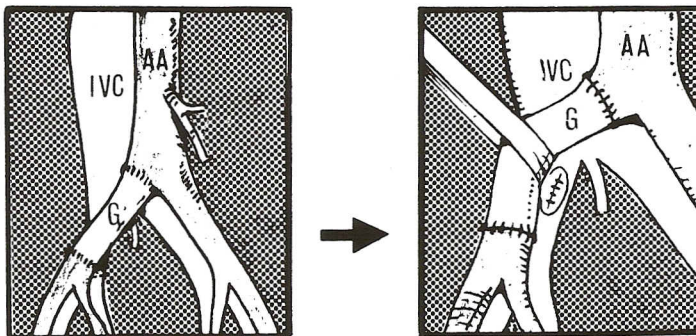


Figure 2. Illustration of the surgical repair of the arteriovenous fistula using a tubular graft. (AA: Abdominal aorta, IVC: Inferior vena cava, G: the synthetic PTFE graft.)

to periarterial haematoma. This weakened the arterial wall and resulted in aneurysm formation which ruptured into the right iliac vein forming an arteriovenous fistula.⁸ Detection of a recent bruit or thrill as well as thorough review of the past medical history led to the correct diagnosis of an arteriovenous fistula after laminectomy. In such cases, early surgical repair is mandatory. The technique used in our case was standard and the one of choice. However, many alternative techniques have been described including the possibility of using the internal iliac artery as a graft when a vascular prosthesis is not available.⁹

References

- Mixer WJ, Barr JS. Rupture of the intervertebral disc with involvement of the spinal cord. *N Engl J Med* 1934; **211**: 210–215.
- Linton RR, White PD. Arteriovenous fistula between the right common iliac artery and inferior vena cava. Report of a case following operation for a ruptured intervertebral disc. *Arch Surg* 1945; **50**: 6–13.
- Holscher EC. Vascular complication of disc surgery. *J Bone Jt Surg* 1948; **30A**: 968–970.
- Seeley SF, Hughes CW, Jahnke EJ Jr. Major vessel damage in lumbar disc surgery. *Surgery* 1954; **35**: 421–425.
- Hildreth DH, Turcke DA. Postlaminectomy arteriovenous fistula. *Surgery* 1977; **81**: 512–520.
- Jarstfer BS, Rich NM. The challenge of arteriovenous fistula formation following disc surgery: a collective review. *J Trauma* 1976; **16**: 726–733.
- Franzini M, Altara P, Annesi V, Codini V. Iatrogenic vascular injuries following lumbar disc surgery. *J Cardiovasc Surg* 1987; **28**: 727–730.
- Marks C, Weiner BN, Redyman M. Arteriovenous fistula secondary to intervertebral disc surgery. *J Cardiovasc Surg* 1971; **12**: 417–424.
- Alvarez HJ, Cazarez JC, Hernandez A. An alternative repair of major vascular injury inflicted during lumbar disc surgery. *Surgery* 1987; **4**: 505–507.