

Transaxillary Abdominal and Lower Limb Arteriography The King Abdulaziz University Hospital Experience

Tarek Rashad Saleh, MSRD, MDRD (Alex)*;
Hasan Ali Al Zahrani, FRCS (Glas)

The authors reviewed their experience with 31 patients with transaxillary abdominal and lower limb arteriography; with particular attention to technical difficulty or any complication related to the procedure. The indication for transaxillary approach were aortic occlusion or stenosis (20/31) common or external iliac occlusion or stenosis (7/31), abdominal aortic aneurysm (2/31), iatrogenic abdominal aortic dissection (1/31) and bilateral femoral artery aneurysm (1/31). Technical difficulties are minimal using single pigtail catheter technique. Difficulties in catheterization can be overcome by the use of catheter exchange technique and thin safety J guide wire (0.028, 0.025 inch). Only one patient out of 31 had minimal insignificant axillary haematoma from the procedure. It was concluded that the use of minicatheters (5F) with minimal catheter exchange and adequate manual compression after catheter withdrawal until complete haemostasis minimize the risk of complications.

Introduction

Percutaneous transaxillary catheterization for arteriography has received considerable attention since 1963^(1,2,3). The left axillary artery has been employed to investigate the abdominal aorta^(4,5). The potential value of this approach is so useful and less hazardous, than translumbar aortography⁽⁴⁾.

Material and Method

This study was done in King Abdul Aziz University Hospital, Jeddah, Saudi Arabia during a 3 years period starting October 1990. It included 31 patients with

abdominal and/or lower limb arteriography done through transaxillary approach.

The relatively small number of cases is due to the fact that we prefer the femoral approach to the abdominal aorta.

Techniquely the patient lies supine with the arm extended. The elbow is flexed so that the head is resting on the palmar surface of the hand or palmar surface of the hand is just cephalad to the head.

The axillary artery is carefully localized distal to the insertion of pectoralis major muscle. Local anaesthesia with approximately 10 ml xylocaine 2% followed by Seldenger needle puncture using thin walled arterial cannula gage 18.7 cm in length; then J-shaped 0.038-0.035 guide wire is advanced under fluoroscopic control only when free blood flow from the cannula is maintained to avoid intimal injury or partial dissection.

After withdrawal of the cannula, 100 cm 5 - 5.5 F Pigtail super Torque aortic flush

From the Departments of Radiology and Surgery, King AbdulAziz University Hospital, P.O. Box 6615, Jeddah 21452, Kingdom of Saudi Arabia.

Address for Correspondence: Dr. Tarek Rashad Saleh, Department of Radiology, King Abdul Aziz University Hospital, P.O. Box 6615, Jeddah 21452, Kingdom of Saudi Arabia.

catheter is advanced, the catheter is rotated with the guide wire within the aortic arch so that the ring projects toward the patient's left, then the guide wire is advanced, so the pigtail gradually opens and wire swings to the descending aorta. Pigtail catheter is advanced to the lower dorsal or upper abdominal aorta followed by DSA run at the abdomen (or any region of interest) with manual injection of 10-15 ml Iohexol (Omnipaque 350 mg). Regular films are then taken with pulk film changer and table shift (Angiotron) using a bollus of 60 ml Omnipaque 350 mg at a rate ranging between 10-15 ml/sec. Following removal of the catheter complete hemostasis must be achieved by compressing the axillary artery proximal to the site of puncture 10-15 minutes until complete haemostasis. Patient is transferred into the ward and kept under observation for 24 hours. Particular attention was directed to any complication related to the procedure including axillary haematoma, axillary artery pseudo-aneurysm, arterio-venous fistula and upper extremity neurologic complications.

Results

- The age incidence of our patients ranged between 33-90 years, with male to female ratio of 28:3.
- The clinical manifestations were lower limb ischaemia (29/31) and pulsatory abdominal or inguinal masses (query aneurysm).
- The main clinical indication for axillary puncture was absent or extremely weak femoral pulses (26/31), unsuccessful attempt at catheterization via the femoral artery because of very tight common and external iliac stenosis (1/31) and guide wire fails to pass aortic bifurcation abdominal aortic aneurysm (2/31), bilateral femoral artery aneurysm (1/31) and iatrogenic aortic dissection (1/31).

Technically, by single pigtail catheter technique using 0.038-0.035 inch guide wire

we succeeded in catheterization of the abdominal aorta through axillary puncture in 29/31 patients. In two of our patients, single pigtail catheter fails to enter into the descending aorta. In the first patient the left subclavian artery was tortuous, kinked with multiple aneurysms (Fig. 1). The only method that succeed to pass such tortuosity and kinking when it was impossible, was the use of 0.028 inch guide which was rather soft and malleable. In the other patient, the failure was attributed to the severe acute left subclavian aortic angle which made guide wire pass always to ascending aorta. This difficulty was overcome by the use of (catheter exchange technique) where a copra catheter was used to direct the guide wire to the descending aorta, then the catheter was changed by pigtail catheter for the flush aortography⁽⁴⁾.

- All our patients were closely supervised after arteriography for any complication and no complication whatsoever has been recorded, except for small insignificant axillary haematoma, which occurred in the patient with catheter exchange technique.

The angiographic findings in our patients were as follows:

- Low aortic, (below renal) occlusion or stenosis 17/31 (Fig. 2).
- High aortic (above renal) occlusion or stenosis 3/31.
- Common or external iliac artery occlusion or stenosis 7/31 (Fig. 3).
- Abdominal aortic aneurysm 2/31 (Fig. 4).
- Iatrogenic aortic dissection 1/31.
- Bilateral femoral artery aneurysm 1/31 (Fig. 1).

Discussion

Early studies showed that axillary puncture for abdominal aortography is technically more difficult⁽⁶⁾. Many difficulties have been encountered with left axillary catheterization. These include guide wire enters the ascending aorta as most

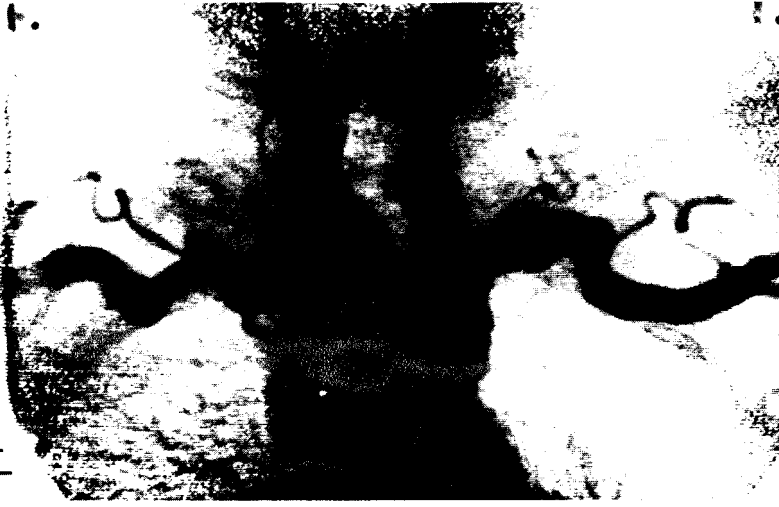

Fig.1(A): Arch aortogram Multiple aneurysm and kinks of both subclavian arteries only 0.028 J guide wire succeed to enter the aortic arch because of advanced kinking and tortuosity.

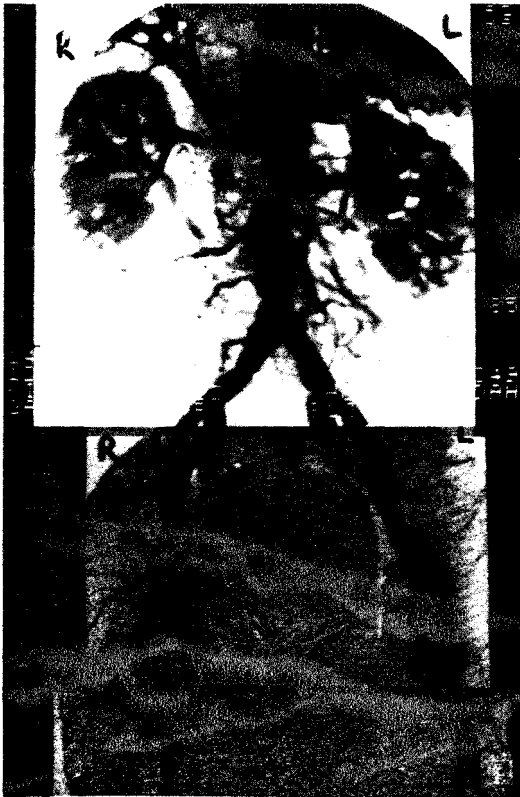

Fig.1(B) Distal abdominal and lower limb arteriography for the sample patient in (A) showing multiple abdominal, external iliac and femoral aneurysms, Note the large fusiform aneurysms of both femoral arteries that make trans-femoral approach hazards.

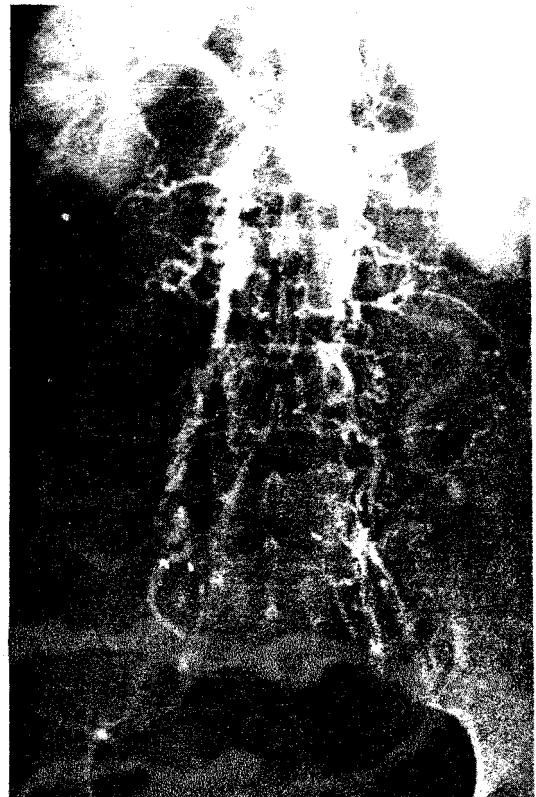


Fig. 2: Occlusion of the abdominal aorta distal to the origin of both renal arteries with abundant collaterals through lumbar arteries that could faintly opacify both external and internal iliac arteries. Note: Stenosis of Rt. renal artery.

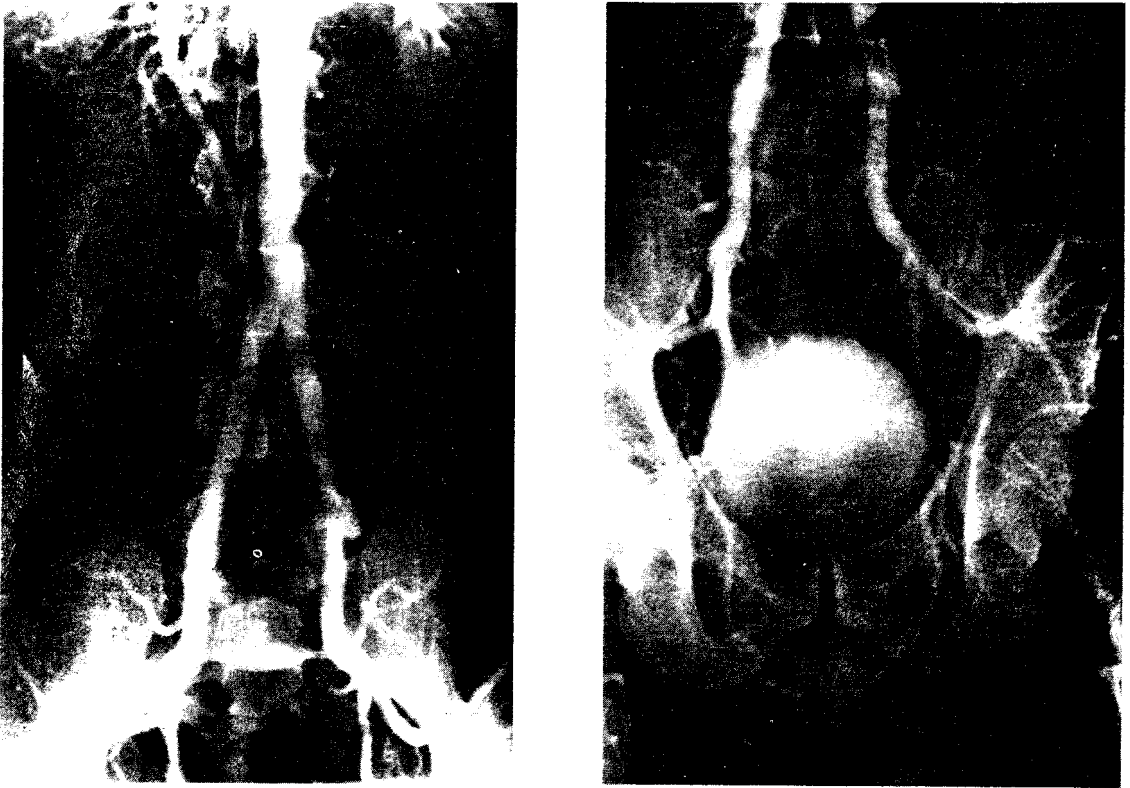


Fig.1(A,B): Bilateral external iliac artery occlusion with abundant collaterals through internal iliac that opacify both profunda femoris arteries.

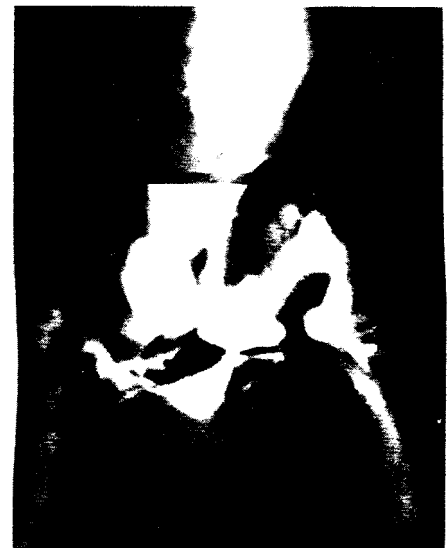

Fig. 4(A): CT dissecting abdominal aortic aneurysm with partial mural wall thrombosis.
(B): Transaxillary abdominal aortogram of the same patient in (A) showing fusiform abdominal aortic aneurysm with delayed filling of the dissecting sac.

frequently occurs in the older age group. Guide wire is deflected into the long thoracic instead of passing down the Lt. subclavian artery into the aortic arch (Bron 1966)⁽⁴⁾.

Several techniques have been used to pass a catheter via left axillary artery into the descending thoracic aorta and abdominal aorta. These have included the use of a double catheter (Hanafee 1963)⁽¹⁾, (Riley 1965)⁽⁷⁾... multiple - curve guide wire, (Miller 1969)⁽⁸⁾, a deflector catheter (Hawkins 1972)⁽⁹⁾ and single pigtail catheter (Glen 1975)⁽⁵⁾.

In our study single pigtail catheter technique was successful (30/31 patient). Failure was only reported in one patient where double catheter exchange technique was used.

Recently McIvor & Thymer, 1992⁽¹⁰⁾ concluded that transaxillary arterial catheterization has a high rate of technical success (99%) and should be considered where the femoral route is contraindicated due to arterial disease.

Axillary puncture for abdominal aortography is the only approach that carries the risk of cerebrovascular accident⁽⁶⁾. Molnar et al 1972⁽¹¹⁾ analyzed 1,762 consecutive studies for complication of axillary arteriography. They reported that only 0.5% suffered major complications; these include, local thrombosis, axillary haematoma, with motor deficit, pseudo-aneurysm and pseudoaneurysm, with motor deficit.

Smith et al 1989⁽¹²⁾ reviewed over 13 years period 320 patients with trans-axillary arteriography for neurological complication; they found that less than 1% suffered motor and sensory nerve injury, sensory involvement were transient and resolved spontaneously.

Many authors suggested that only motor symptoms should be treated surgically as early decompression was usually successful^(11,13,14).

Smith et al⁽¹²⁾ reported also that large number of complications occurred in

patients who underwent transaxillary PTA especially when using standard 7F catheter.

Fortunately, none of the previously mentioned complications had been reported in our series except for minimal insignificant axillary haematoma which occurred with catheter exchange technique. The low complication rate in our study; can be due to the use of small french catheter (5F), use of J-shaped guide wire, minimal catheter exchange using single pigtail catheter technique and manual compression after the procedure was applied until complete hemostasis was achieved (usually 10-15 min.).

Conclusion and Recommendation

1. Transaxillary catheterization of abdominal aorta is a safe easy technique.
2. Single pigtail catheter technique for abdominal aortography is an easy method with less complication.
3. Small catheters carry less risk of complication.
4. Complication at the puncture site can be minimized by application of adequate pressure at the entry point when the catheter is withdrawn.

References

1. Hanafee W. Axillary artery approach to carotid, vertebral, abdominal aorta and coronary angiography. *Radiology* 1963; 81: 559-567.
2. Newton TH. Axillary artery approach to arteriography of aorta and its branches. *AJR* 1963; 89: 275-283.
3. Roy P. Percutaneous catheterization via axillary artery; new approach to some technical road-blocks in selective arteriography. *AJR* 1965; 94: 1-17.
4. Bron KM. Selective visceral and total abdominal arteriography via

- the left axillary artery in the older group. *AJR* 1966; 97: 432-437.
5. Glenn JH. Abdominal aorta catheterization via the left axillary artery. *Radiology* 1975; 115: 227-228.
 6. Crummy AB. Arteriography of the patient with previous aortoiliac surgery. In: Abrams HL ed. *Abrams Angiography vascular and interventional radiology* 3rd ed. Little, Brown and Company, Boston, 1983.
 7. Rile JM, Hanafee W, Weidner W. Left maxillary approach to the abdominal aorta. *Radiology* 1965; 84: 96-99.
 8. Miller RE, Chua GT. Multiple-curve guide wire for aortic catheterization. *Radiology* 1969; 92: 1569- 1570.
 9. Hawkins IF. A deflector catheter approach to the abdominal aorta. *AJR* 1972; 116: 196-198.
 10. McIvor J, Rhymer JC. 245 transaxillary arteriograms in arteriopathic patients: success rate and complications. *Clin-Radiology* 1992; 46(6): 390-4.
 11. Molnar W, Paul DJ. Complication of axillary arteriotomies. An analysis of 1,762 consecutive studies. *Radiology* 1972; 104: 269-276.
 12. Smith DC, Mitchell DA, Peterson GW, Will AD, Mera SS, Smith LL. Medial brachial fascial compartment syndrome: Anatomic basis of neuropathy after transaxillary arteriography. *Radiology* 1989; 173: 149-154.
 13. Lyon BB, Hansen BA, Mygind T. Peripheral nerve injury as a complication of axillary arteriography. *Acta Neurol Scand* 1975; 51: 29-36.
 14. Braun RM, Neman J, Thacher B. Injury to the brachial plexus as a result of diagnostic arteriography. *J Hand Surg* 1978; 3; 90-94.