

Manchester repair

An alternative to hysterectomy

Abdulrahim A. Rouzi, MBChB, FRCSC, Nora N. Sahly, MBChB, Amal S. Shobkshi, MD, Hassan S. Abduljabbar, MBChB, FRCSC.

ABSTRACT

الدراسات الموجودة حالياً لا تتوفر أية معلومات فيما يخص عمليات (مانشستر). نستعرض في هذا التقرير وبأثر رجعي سلسلة من الدراسات لسبع سيدات كن يعانين من هبوط في الرحم، وخضعن لعملية (مانشستر)، وذلك خلال الفترة ما بين يناير 1997م وحتى مايو 2008م، بمستشفى الملك عبد العزيز الجامعي - جدة - المملكة العربية السعودية. وقد مرت جميع هؤلاء السيدات بمراحل الحمل والولادة ولدين (1±3) أبناء، ويرغبن في تفادي عملية استئصال الرحم وإنجاب المزيد. تراوحت مدة العملية ما بين 119±16 دقيقة، ولم يكن هناك أية مضاعفات خلال العملية. تراوحت مدة المتابعة ما بعد العملية 2±5 أعوام. كانت جميع السيدات راضيات عن نتائج العملية. حملت مريضتين (28.6%) وكانت ولادتهن طبيعية وناجحة. تعتبر عملية (مانشستر) البديل المناسب لاستئصال الرحم للسيدات اللاتي يعانين من هبوط في الرحم من الدرجة الثانية ويرغبن في الإنجاب.

Local data regarding Manchester repair are not available in the current literature. We report a retrospective case series of 7 women who presented with uterine prolapse, and underwent Manchester repair from January 1997 to May 2008 at King Abdulaziz University, Jeddah, Kingdom of Saudi Arabia. All of these women were multiparous (para 3±1) and wanted to avoid hysterectomy, and become pregnant. The duration of the procedure was 119 ± 16 minutes. No operative complications were observed. The mean duration of follow up was 5±2 years. All of the women were satisfied with the procedure. Two (28.6%) patients subsequently became pregnant and had a successful vaginal delivery. Manchester repair is a valid alternative to hysterectomy for women with a second degree uterine prolapse who want to preserve their fertility.

Saudi Med J 2009; Vol. 30 (11): 1473-1475

From the Department of Obstetrics and Gynecology, King Abdulaziz University, Jeddah, Kingdom of Saudi Arabia.

Received 23rd February 2009. Accepted 14th April 2009.

Address correspondence and reprint request to: Prof. Abdulrahim A. Rouzi, Department of Obstetrics and Gynecology, King Abdulaziz University, PO Box 80215, Jeddah 21589, Kingdom of Saudi Arabia. Tel. +966 505602587. Fax +966 (2) 6408316. E-mail: aarouzi@gmail.com

Uterine prolapse is defined as the descent of the uterus and cervix into the vaginal canal toward the introitus. Some degree of uterine prolapse is common in parous women; however, symptomatic uterine prolapse is not common in women during their reproductive years. Treatment options include both non-surgical and surgical modalities, but the failure rate is high with non-surgical approaches. Surgical options, in particular vaginal hysterectomy, are therefore the standard treatments in these cases. Hysterectomy may not, however, be acceptable to young women with a second degree uterine prolapse who want to preserve their fertility. In this group of patients, the Manchester-Fothergill procedure (commonly referred to as the Manchester repair) should be considered. This procedure was first performed in 1888 by Dr. Archibald Donald in Manchester, England,¹ and comprises an anterior and/or posterior colporrhaphy with amputation of the cervix and suturing of the cardinal ligaments to the anterior cervical stump. Only a limited amount of information exists in the current literature regarding this surgical method.² The aim of the current study was to report on our local experience with this rare procedure in young women with uterine prolapse who do not wish to have a hysterectomy and want to become pregnant.

Case Report. All of the operative records from January 1997 to May 2008 at King Abdulaziz University Hospital in Jeddah, Kingdom of Saudi Arabia were reviewed. The records for women who had suffered from a uterine prolapse and had subsequently undergone Manchester repair were identified and examined. Consent was obtained before surgery. Institutional Review board approval was obtained as appropriate. Data regarding age, clinical presentation, operating time, estimated blood loss, presence of intraoperative and postoperative complications, duration of admission to the hospital, and long-term follow-up were extracted from these specific files. Statistical analysis (mean±SD) was calculated as appropriate. Seven women underwent Manchester repair procedure in our hospital as described previously³ without any personal modifications. The

major steps included detachment, suturing, and reattachment of both cardinal and uterosacral ligaments to the anterior aspect of the cervix; amputation of the cervix; and covering of the cervical stump with vaginal mucosa, as per the Sturmdorf technique (Figures 1-4).³ The amputated cervix measured 4 ± 2 cm. The mean age was 32.4 ± 5.2 years and parity of 3 ± 1 . All of these women presented with a protruding mass from the vagina. In addition, one (14.3%) woman complained of stress incontinence, and an additional individual complained of lower back pain. No urodynamics were used. The duration of the procedure was 119 ± 16 minutes, and the average hospital stay was 6.3 ± 1 days. The blood loss was 300 ± 70 ml. No operative complications were observed, although one of the women developed postoperative fever. All of the women were satisfied with the procedure. Two (28.6%) patients subsequently became pregnant and had a successful vaginal delivery with elective episiotomy at term. No antepartum complications occurred and no cervical cerclage was used. The other 5 women did not get pregnant spontaneously and did not seek medical advice regarding assisted reproductive technologies. An additional 2 women from this cohort experienced posterior vaginal wall prolapse at 5 and 7 years post-surgery and underwent posterior colporrhaphy. The other 5 women had a good anatomic result and no symptoms of prolapse recurrence.

Discussion. Uterine preservation following pelvic prolapse is a concept that has been pursued for quite some time. In fact, as early as 1934, Bonney⁴ described the uterus as a passive player in the uterovaginal prolapse. More recently, the pericervical fascia has been described as the cornerstone of pelvic reconstruction.⁵ As women are delaying childbearing into later years, techniques for the preservation of the uterus are even more critical. The Manchester repair procedure has been performed to preserve the uterus following prolapse for over 100 years. In addition, although no difference in complication rates has been reported for the Manchester repair and the more common vaginal hysterectomy, surgery time and total blood loss are typically less during the Manchester procedure, suggesting that this procedure may be safer than a vaginal hysterectomy.⁶ This procedure is not, however, the gold standard treatment for uterine prolapse, perhaps due to reported recurrence of prolapse in the first few months,⁷ a subsequent drop in fertility to 21-33%,^{8,9} and pregnancy wastage of up to 50%.¹⁰ Chaudhuri⁹ reported an increase in spontaneous abortion and pre-term labor following the procedure; however, the age of the patient at conception may also be a causative role in these cases. In addition, due to the nature of this procedure, cytological sampling of the cervix and

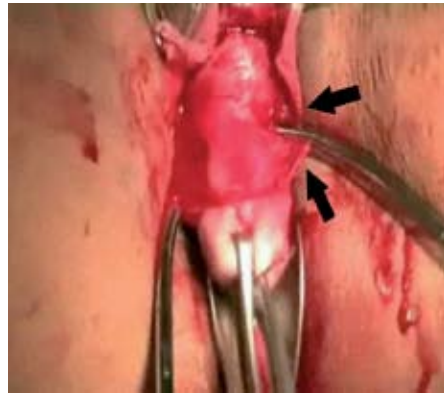


Figure 1 - The vaginal mucosa is dissected and the cardinal ligament is clamped.

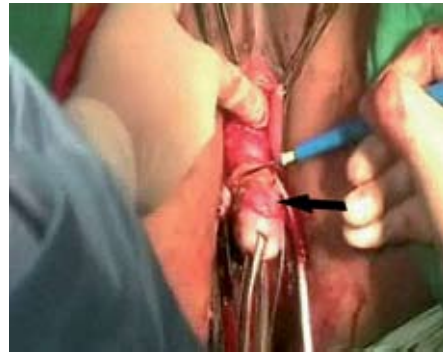

Figure 2 - The cervix is amputated.

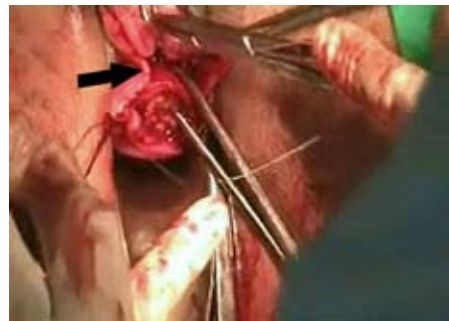


Figure 3 - Sturmdorf suture is placed.

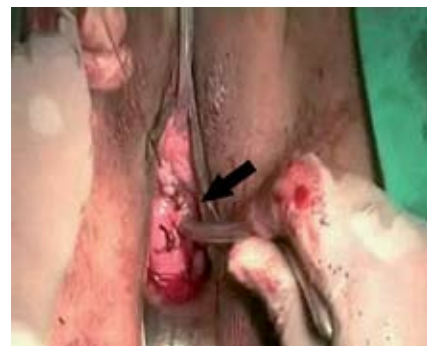

Figure 4 - Patency of the cervix is confirmed.

the endometrium for histologic examination is limited following the repair due to vaginal re-epithelialization or cervical stenosis. In this study, however, only 2 women experienced a recurrence of posterior vaginal wall prolapse. Although this number represents close to 30% of the subjects, the women experienced a recurrence 5 and 7 years after the procedure was performed, and this time frame is likely sufficient to preserve fertility and allow childbearing. In addition, 2 (28.6%) of the women achieved pregnancy following the procedure and had vaginal deliveries, demonstrating the utility of preserving the uterus in young women with uterine prolapse. Furthermore, the safety of this procedure was confirmed as no surgical complications and minimal postoperative complications were observed. Despite the obvious benefits of this procedure, the number of ideal candidates for its implementation is limited. Conservative laparoscopic suspension surgery or use of a sling is probably most useful for young patients with prolapse who wish to keep their uterus intact as these techniques are least invasive and preserve fertility the best, while vaginal hysterectomy with anterior and posterior repair is most appropriate for women experiencing prolapse who do not desire future fertility.² The Manchester repair, which, according to our results, is a safe and relatively effective repair procedure, is then most useful for young patients experiencing recurrence of uterine prolapse with cervical elongation following a surgical suspension procedure.²

In conclusion, according to the results described here, women who undergo a Manchester repair are satisfied with the results of the procedure. This fact in combination with the low complication and morbidity

rates following the surgery support the continued use of this repair procedure for the treatment of uterine prolapse in women who wish to keep their uterus. All factors must be weighed, including the desires of the patient, before a surgical plan is ultimately determined, but the Manchester procedure is certainly an option worth considering for the treatment of uterine prolapse.

References

1. Donald A. The operative treatment of prolapse of the uterus and vagina. *J Obstet Gynecol Br Emp* 1902; 1: 312-326.
2. Skiadas CC, Goldstein DP, Marc R, Laufer MR. The Manchester-Fothergill procedure as a fertility sparing alternative for pelvic organ prolapse in young women. *J Pediatr Adolesc Gynecol* 2006; 19: 89-93.
3. Ayhan A, Esin S, Guven S, Salman C, Ozyuncu O. The Manchester operation for uterine prolapse. *Int J Gynecol Obstet* 2006; 92: 228-233.
4. Bonney V. The principles that should underline all operations for prolapse. *J Obstet Gynaecol Br Empire* 1934; 41: 669-683.
5. Ross JW. Apical vault repair, the cornerstone of pelvic vault reconstruction. *Int Urogynecol J* 1997; 8: 146-152.
6. Thomas AJ, Brodman ML, Dottino PR, Bodian C, Friedman Jr F, Bogursky E. Manchester procedure vs. vaginal hysterectomy for uterine prolapse. *J Reprod Med* 1995; 40: 299-304.
7. Williams BFP. Surgical treatment in uterine prolapse in young women. *Am J Obstet Gynecol* 1966; 95: 967-971.
8. Fisher J. The effect of amputation of the cervix uteri upon subsequent parturition. *Am J Obstet Gynecol* 1951; 62: 644-648.
9. Chaudhuri S. The place of sling operations in treating genital prolapse in young women. *Int J Gynaecol Obstet* 1979; 16: 314-320.
10. O'Leary JA, O'Leary JL. The extended Manchester operation. *Am J Obstet Gynecol* 1970; 107: 546-550.

Related topics

Zangana AM. Twisted mixed germ cell tumor of the ovary in a child. *Saudi Med J* 2006; 27: 1240-1243.

Khan FY. Unusual cause of dysphagia. *Saudi Med J* 2005; 26: 1303-1304.

Al-Ghamdi FA, Al-Khattabi MA. Ovarian mucinous cystadenocarcinoma of low malignant potential associated with a mature cystic teratoma. *Saudi Med J* 2006; 27: 1412-1414.

Sait KH, Alkhattabi MA, Alkushi AO, Alqahtani MH. Ovarian mucinous cystadenoma in a female with Turner syndrome. *Saudi Med J* 2004; 25: 1270-1273.