

Determination of Portal Shunt Index Using 123-Iodoamphetamine Transrectally

ABDULRAOF A. MAIMANI, ABR, ABNM¹,
ADEL M. KHAZINDAR, FRCP(P)², and MOHAMMED A. AL HARBI, FRCS(C)³
¹*Department of Diagnostic Imaging, ²Department of Medicine,
and ³Department of Surgery, Faculty of Medicine,
King Abdulaziz University, Jeddah, Saudi Arabia*

ABSTRACT. Liver cirrhosis with portal hypertension is one of the leading causes of death in Saudi Arabia. There are different modalities of investigation and treatment, the method which denotes the best way of treatment, is not yet discovered. 123-Iodoamphetamine was injected through the rectum in 17 patients. Sequential images of the chest and upper abdomen were obtained for 1 hour. Shunt index was calculated. There was a high correlation between Child's classification and shunt index. For Class C, all have shunting index of 100%. We found that 123-Iodoamphetamine method is a simple and non-invasive method in the assessment of patients with liver cirrhosis.

Keywords: Shunting index, Portal hypertension, 123-Iodoamphetamine.

Introduction

Liver cirrhosis with portal hypertension is one of the leading causes of death in Saudi Arabia^[1]. There are different modalities of investigation and treatment, the method which denotes the best way of treatment, is yet to be discovered.

Portal hypertension with oesophageal varices is the most common cause of acute upper gastrointestinal (GI) bleeding in Saudi Arabia and reflects the high

Correspondence & reprint requests to: Dr. Abdulraof A. Maimani

P.O. Box 11853, Jeddah 21463 Saudi Arabia

Accepted for publication: 16 February 2005. Received: 01 May 2004

incidence of Schistosomiasis and Hepatitis B infection in our population. There are different types of treatment ranging from drugs (Propranolol^[2], Somatostatin^[3], Vasopressin^[4] & Ca Channel blockers^[5]) to endoscopic sclerotherapy^[6] or ligation^[7] to different types of surgical operations (*e.g.*, Sugiura^[8], modified Sugiura and various kinds of portosystemic shunts^[9]). This suggests that there is no single specific way of treatment for this disease.

The pharmacological treatment of portal hypertension as a long-term definitive way to control variceal hemorrhage is apparently the most intense area of clinical research and investigation in portal hypertension^[10].

The better understanding of the patho-physiological changes in portal hypertension will eventually improve the way of treatment.

In patients with progressive liver disease, the onset of portosystemic shunting is an important milestone in the course of their disease. The aim of our study is to detect and quantify portosystemic shunts, which will affect the prognosis and treatment of these patients.

Methods

The following steps were undertaken:

- All our patients have liver cirrhosis proven by clinical examinations and laboratory tests.
- All our patients fasted for 8 hours and had a fleet enema done in our department 1 hour before the procedure.
- While the patient was in left lateral decubitus position, a 17F catheter was inserted through the anus and advanced 20 cms (to avoid systemic absorption of the tracer).
- 2 mls of 123-Iodoamphetamine (IMP) (1mCi) were injected followed by 20 cc of air. The patient then lies on his/her back and sequential images of the lungs and upper abdomen anteriorly are taken every 1 minute for 1 hour. Regions of interest were defined and the time activity curves of the liver and lungs were obtained.
- The portosystemic shunt index was estimated with the formula:

$$\text{Shunt Index} = \frac{\text{Counts of lungs}}{\text{Counts of (liver + lungs)}} \times 100\%$$

- After the curve becomes steady, 45 minutes were chosen as the point to measure the counts.
- Preparation of the pharmaceuticals was done in King Faisal Specialist Hospital & Research Center, Riyadh.

We obtained the IMP from CIS Company in France. This was labeled in Riyadh with strict Radiopharmaceutical Quality Control and shipped to Jeddah a day before the examination on request.

Child's classification for liver cirrhosis was determined for each patient. All our patients were between Class B and Class C.

Results

In all the patients, images of liver and/or lungs were observed within 5-10 minutes after administration of IMP these became clearer with time.

In a patient without liver disease, only liver was demonstrated 60 minutes after IMP administration (Fig. 1). We had only one case who was a volunteer.

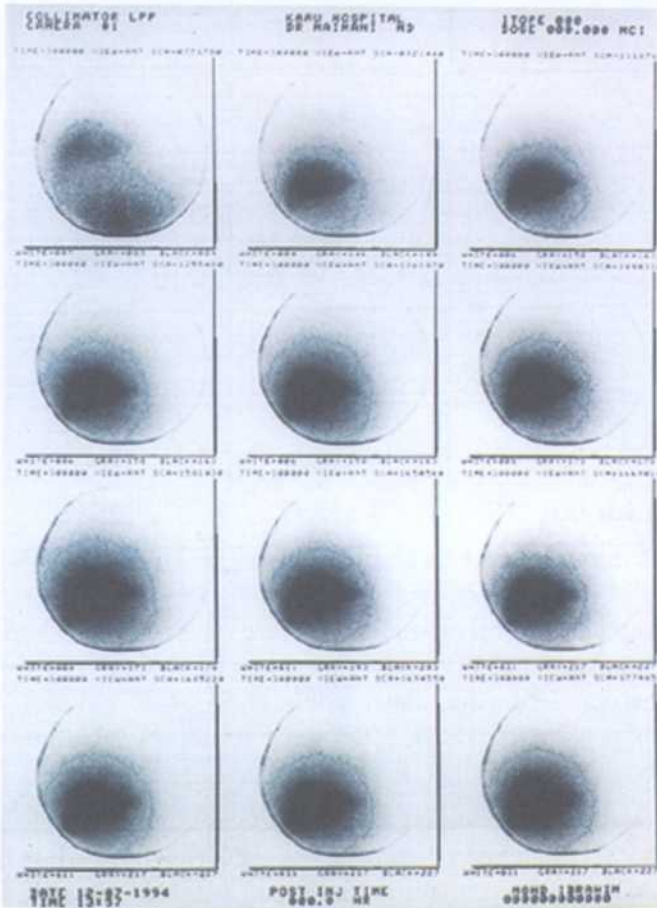


FIG. 1. Shows uptake in the liver alone. This is a normal study.

In patients with liver cirrhosis, images of both lungs and liver or the lungs alone were clearly seen (Fig. 2).

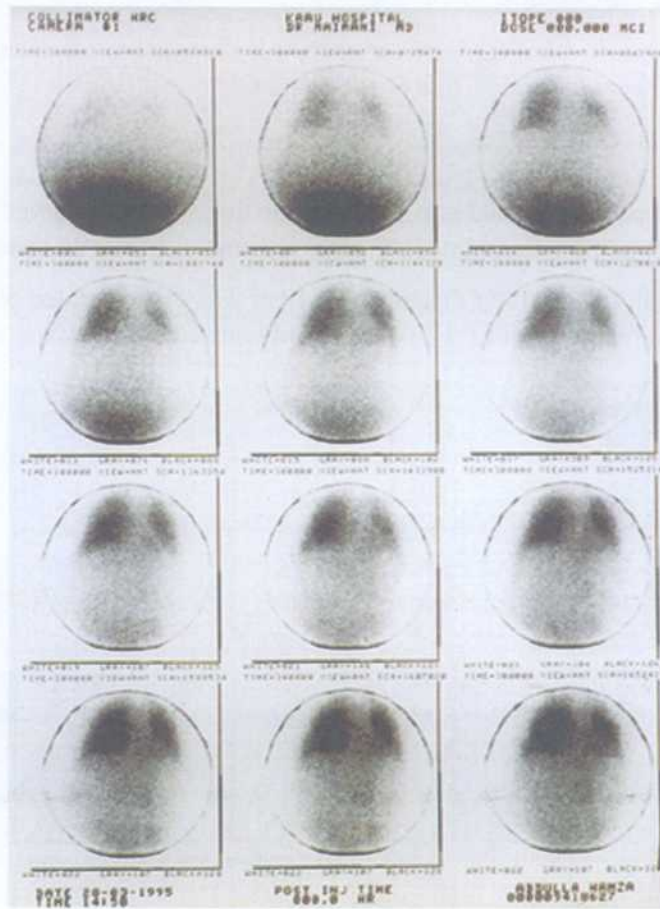


FIG. 2. Shows uptake in the lungs alone. Shunt index 100% in this patient.

Time activity curves of liver and lungs were obtained for at least 60 minutes after IMP administration. The shunt index was taken from counts at a point of time when the curve becomes flat, usually at 45 or 50 minutes (Fig. 3). The shunt index is considered 100% when the liver is not seen during the whole study.

All our patients were between Class B and Class C (Child's classification) of liver cirrhosis. We included 17 cases in our study; 10 from Class B and 7 from Class C. A very high correlation was found between class of cirrhosis and shunt index. P-value was less than 0.001.

The correlation coefficient (r) was equal to 0.8454 using Spearman rank correlations. In Class B, the range was between 31% - 81% with a mean = 65 STD + 14.91. For Class C, all have a shunting index of 100%.

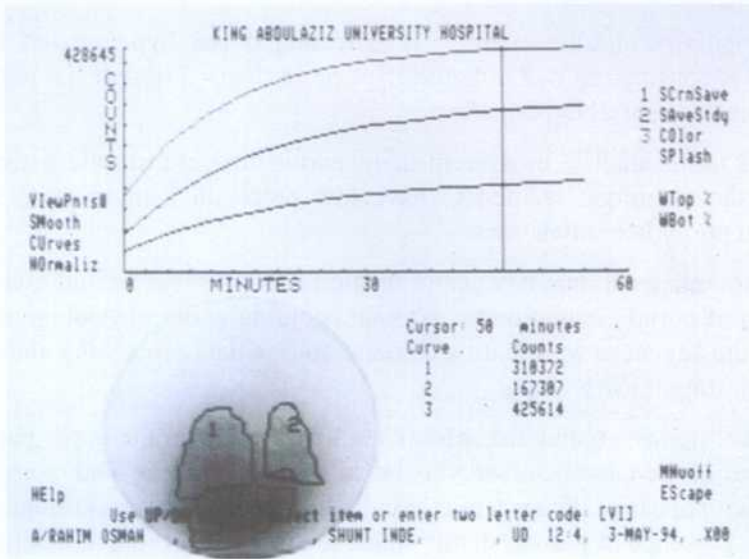


FIG. 3. Shows uptake in the lungs and liver as well as the compute generated curves, time against count.

Discussion

In patients with progressive liver disease, onset of portosystemic shunting is an important milestone in the course of their disease. The ability to detect and quantify portosystemic shunts can affect the prognosis and treatment of these patients.

In asymptomatic chronic hepatitis patients, the onset of cirrhosis is associated with a poor prognosis. Detection of portosystemic shunts using transcolonic radioisotope studies has been used to distinguish patients with and without cirrhosis and to identify patients with liver decompensation and has been proposed as an alternative to liver biopsy as a method of identifying those patients with poor prognosis in whom more aggressive therapy may be warranted^[11,12].

The magnitude of portosystemic shunting has been correlated with the incidence and severity of specific complications of cirrhosis such as hepato-encephalopathy and variceal bleeding^[13, 14].

There are several ways of investigation to detect the patho-physiological changes in portal hypertension and these include the following:

Arterial portography (either superior mesenteric or splenic), hepatic wedge (HWP) measurement and wedge venography are used to assess portal hypertension. However, such techniques are invasive and cannot be used repetitively to evaluate progress of patients.

The sensitivity of ultrasound^[15] in detecting portal hypertension is about 40%, this is considering that a diameter of more than 13 mm of the portal vein an indication for portal hypertension.

Doppler ultrasound^[16] measurement of portal flow in cirrhotic patients was tried but the technique seemed to have low precision in monitoring chronic changes in portal hemodynamics.

Radioisotopic technique is a useful method for non-invasive and quantitative evaluation of portal circulation by external counting under physiological condition with the advent of scintillation camera, on-line data processing and suitable gamma emitting tracers.

In normal portal circulations, tracers are absorbed from the upper part of the rectum and carried to the liver via the inferior mesenteric and portal veins. They do not appear in the systemic circulation without passing through the liver. In the presence of portosystemic shunt such as hemorrhoidal plexus, esophageal varix and intrahepatic shunt, the tracer appears in the systemic circulation directly via the portosystemic shunt. Therefore, we can evaluate the existence of portosystemic shunting by detecting tracer in the systemic circulation^[12].

Technetium-99m (Tc 99m) pertechnetate has been used to study portosystemic shunting^[17,18] but IMP is a superior technique. In the case of Tc 99m pertechnetate the time activity curve over liver-heart are influenced by other factors such as absorption of 99mTc from the rectum, portal circulation time and location of porto-systemic shunt. Furthermore, 99mTc in pertechnetate state passes through the liver rapidly and distributes extravascularly. These physiological properties complicate the use of 99mTc pertechnetate to evaluate portosystemic shunting.

Tonami in 1982^[19] reported Thallium 201 (Tl-201) chloride as a new tracer for evaluation of portosystemic shunting.

Since Tl-201 is taken up and retained by the liver and heart, the heart to liver uptake ratio after rectal administration of Tl-201 was used as a shunt index. This method is not ideal, only a small fraction of Tl-201 entering the systemic circulation is taken up by the heart, the remainder distributes diffusely through the body. This causes it to recirculate through the liver and as a result, portosystemic shunting is underestimated. Another problem is low absorption from the rectum in some cases.

This method was used before by Kashiwagi *et al.* [12]. This group used IMP. They injected 2-3mCi, then imaged for 60 min. In their study, they found that the shunt index was high in patients with liver cirrhosis, especially in the de-compensated stage.

Their results also show that the shunt index was 0% in patients without liver disease. Mean was $51.2 \pm 31.6\%$ in patients with compensated liver cirrhosis and $88.8 \pm 14.7\%$ in patients with decompensated liver cirrhosis.

Habu *et al.* studied the correlation between branched amino-acids and portosystemic shunt[20]. But we are the first group comparing this test with Child's criteria. In our technique, we used lower dose (1mCi), which gave us less scattered radiation to the liver.

Our results showed a high correlation between the shunt index and the Child's criteria (Table 1). The test was safe and easy to do. The major drawback of this method was the high cost of IMP and I-123. With good cooperation from the King Faisal Specialist Hospital & Research Center in Riyadh, we were able to receive the I-123 IMP on the next day after shipment.

TABLE 1. The child class and shunt index value for each patient.

Child Class	Shunting Index
C	100%
B	31%
B	61%
B	70%
B	51%
C	100%
B	77%
C	100%
B	63%
B	81%
C	100%
B	78%
B	68%
C	100%
B	70%
C	100%
C	100%

In our results, all Child's group C shunt index were 100%. In Child's group B group, the range was between 31% - 81%. The correlation coefficient (r) was equal to 0.8854 using Sperman rank correlation, which signifies a high correlation.

In our study, the portal scintigraphy was done using only inferior mesenteric vein. I-123 IMP could be used orally to assess the superior mesenteric vein alone, or also, it can be used in combination with transrectal I-123 IMP to assess both superior and inferior mesenteric veins. This could be a new area for further studies.

Conclusion

In conclusion, we found this is to be a simple non-invasive method, easy to use and helpful in the assessment of patients with liver cirrhosis.

References

- [1] **al-Kraida A, Qazi SA, Shaikh MU, Asi SA, al-Mofarreh MA, al-Turki M.** Trans-abdominal gastro-oesophageal devascularization and oesophageal transection for bleeding oesophageal varices. *Br J Surg* 1989; **76(9)**: 943-945.
- [2] [No authors listed] Propranolol for prophylaxis of bleeding in cirrhotic patients with large varices: a multicenter, randomized clinical trial. The Italian Multicenter Project for Propranolol in Prevention of Bleeding. *Hepatology* 1988; **8(1)**: 1-5.
- [3] **Somerville KW, Henry DA, Davies JG, Hine KR, Hawkey CJ, Langman MJ.** Somatostatin in treatment of haematemesis and melaena. *Lancet* 1985; **1(8421)**: 130-132.
- [4] **Valla D, Huet PM, LaFortune M, Marleau D.** Vasopressin perfusion of esophageal varices in cirrhotic patients: cineangiographic study. *Radiology* 1984; **152(1)**: 45-49.
- [5] **Li D.** [Use of calcium-channel blockers in cirrhotic patients with portal hypertension]. *Zhonghua Yi Xue Za Zhi* 1990; **70(7)**: 370-374, 26. Chinese.
- [6] **Moreto M, Zaballa M, Bernal A, Ibanez S, Ojembarrena E, Rodriguez A.** A randomized trial of tamponade or sclerotherapy as immediate treatment for bleeding esophageal varices. *Surg Gynecol Obstet* 1988; **167(4)**: 331-334.
- [7] **Van Stiegmann G, Goff JS, Sun JH, Hruza D, Reveille RM.** Endoscopic ligation of esophageal varices. *Am J Surg* 1990; **159(1)**: 21-26.
- [8] **Sugiura M, Futagawa S.** Esophageal transection with paraesophagogastric devascularizations (the Sugiura procedure) in the treatment of esophageal varices. *World J Surg* 1984; **8(5)**: 673-679.
- [9] **Spina GP, Santambrogio R, Opocher E, Cosentino F, Zambelli A, Passoni GR, Cucchiario G, Macri M, Morandi E, Bruno S, et al.** Distal splenorenal shunt versus endoscopic sclerotherapy in the prevention of variceal rebleeding. First stage of a randomized, controlled trial. *Ann Surg* 1990; **211(2)**: 178-186.
- [10] **Rikker LF.** New concepts of pathophysiology and treatment of portal hypertension. *Surgery* 1990; **107(5)**: 481-488.
- [11] **D'Arienzo A, Celentano L, Scutto A, Di Siervi P, Lombardi V, Squame G, Mazzacca G.** Thallium-201 per rectum for the diagnosis of cirrhosis in patients with asymptomatic chronic hepatitis. *Hepatology* 1988; **8(4)**: 785-787.
- [12] **Kashiwagi T, Azuma M, Ikawa T, Takehara T, Matsuda H, Yoshioka H, Mitsutani N, Koizumi T, Kimura K.** Portosystemic shunting in portal hypertension: evaluation with portal scintigraphy with transrectally administered I-123 IMP. *Radiology* 1988; **169(1)**: 137-140.

- [13] **Bosch J, Mastai R, Kravetz D, Bruix J, Rigau J, Rodes J.** Measurement of azygos venous blood flow in the evaluation of portal hypertension in patients with cirrhosis. Clinical and haemodynamic correlations in 100 patients. *J Hepatol* 1985; **1(2)**: 125-139.
- [14] **Takashi M, Igarashi M, Hino S, Takayasu K, Goto N, Musha H, Ohnishi K, Okuda K.** Portal hemodynamics in chronic portal-systemic encephalopathy. Angiographic study in seven cases. *J Hepatol* 1985; **1(5)**: 467-476.
- [15] **Vilgrain V, Lebrec D, Menu Y, Scherrer A, Nahum H.** Comparison between ultrasonographic signs and the degree of portal hypertension in patients with cirrhosis. *Gastrointest Radiol* 1990; **15(3)**: 218-222.
- [16] **Sabba C, Weltin GG, Cicchetti DV, Ferraioli G, Taylor KJ, Nakamura T, Moriyasu F, Groszmann RJ.** Observer variability in echo-Doppler measurements of portal flow in cirrhotic patients and normal volunteers. *Gastroenterology* 1990; **98(6)**: 1603-1611.
- [17] **Shiomi S, Kuroki T, Kurai O, Kobayashi K, Ikeoka N, Monna T, Ochi H.** Portal circulation by technetium-99m pertechnetate per-rectal portal scintigraphy. *J Nucl Med* 1988; **29(4)**: 460-465.
- [18] **Boldys H, Hartleb M, Rudzki K, Nowak A, Nowak S.** Effect of propranolol on portosystemic collateral circulation estimated by per-rectal portal scintigraphy with technetium-99m pertechnetate. *J Hepatol* 1995; **22(2)**: 173-178.
- [19] **Tonami N, Nakajima K, Hisada K, Tanaka N, Kobayashi K.** A noninvasive method for evaluating portal circulation by administration of Ti-201 per rectum. *J Nucl Med* 1982; **23(11)**: 9659-9672.
- [20] **Habu D, Nishiguchi S, Nakatani S, Kawamura E, Ishizu H, Lee C, Ohfuji S, Fukushima W, Tanaka T, Kawamura T, Shiomi S.** Relationship between branched-chain amino acid to tyrosine ratio (BTR) and porto-systemic shunt in the Child-Pugh grade A cirrhosis determined by per-rectal portal scintigraphy. *Hepatol Res* 2003; **27(1)**: 57-61.

تقييم مقدار تحول الدم من الدورة البابية إلى الدورة الرئيسية باستخدام الأيودوأمفاتمين المعلم باليود المشع

عبد الرؤوف عبدالله ميمني* ، و عادل محمد خزندار** ، و محمد أحمد الحربي***
* قسم الأشعة ، و** قسم أمراض الباطنة ، و*** قسم الجراحة
كلية الطب ، جامعة الملك عبدالعزيز ،
جدة - المملكة العربية السعودية

المستخلص. تم تقييم مقدار تحول الدم من الدورة البابية إلى الدورة الرئيسية باستخدام الأيودوأمفاتمين المعلم باليود المشع. يعتبر تليف الكبد مع ارتفاع الضغط في الدورة البابية من أهم الأسباب للوفاة في المملكة العربية السعودية. هنالك عدة طرق ووسائل لتشخيص وعلاج هذا المرض ، ولكن الوسيلة والطريقة المثلى لم تكتشف بعد. لقد قمنا بحقن الأيودوأمفاتمين المعلم باليود المشع في المستقيم ل ١٧ مريضاً وحصلنا على صور للصدر ومنطقة البطن لمدة ساعة ، وقيس بعد ذلك كمية الدم المتدفق من الدورة البابية إلى الدورة الرئيسية. لقد وجدنا علاقة عالية بين تقسيمة تشايلد لتليف الكبد ومقدار تسرب الدم من الدورة البابية إلى الدورة الرئيسية ، كل المرضى الذين كانوا في تقسيمة تشايلد من الفئة ج كانت كمية التسرب من الدورة البابية ١٠٠٪. لقد وجد أن هذه الطريقة باستخدام الأيودوأمفاتمين المعلم باليود طريقة سهلة في تقييم المرضى الذين يعانون من تليف الكبد.